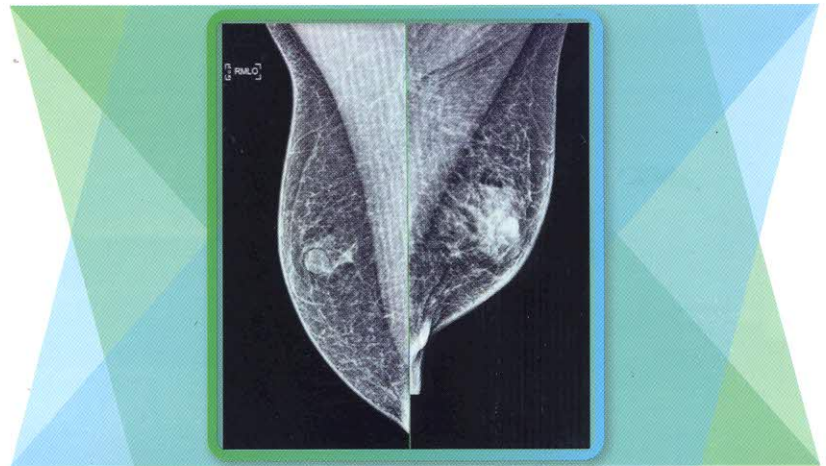


Highlights

- Accuracy of MRI with Cinematic 3D Volume Rendering Reconstruction in Helping the Diagnosis of Partial Thickness Subscapularis Tendon Tear
- Chronic Silicosis as the Potential Consequence of Short-Term Exposure to Silica: A Case Report
- Intradiploic Epidermoid Cyst Mimics a Bone Tumor: A Case Report

Chronic Idiopathic Granulomatous Mastitis in a Male Patient

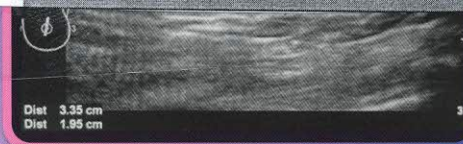

The mediolateral oblique (MLO) view of mammography. Irregular left retroareolar mass with retracted nipple.

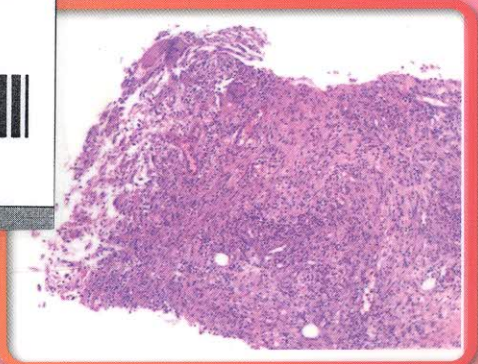
The Bangkok Medical Jou
SERIALS



007305
bib:13399127299



Ultrasonography of the patient's left breast mass. Irregular retroareolar lesion



Histological findings of the core needle biopsyspecimen from patient's left breast mass. Granulation tissue with foreign body giant cells.

Detailed description is given on pages 33-38



Editorial

- E **The Bangkok Medical Journal's Editor**

Original Articles

- 1 **Effects of the Health Promotion Model Development Program on the Quality of Life of the Elderly using Local Wisdom and Ways of Life**
Sutin U, Kumsi S, Sukprasan T, Prasert V, Hathoung D, Sripinyo P, Yamchuen P
- 8 **Accuracy of MRI with Cinematic 3D Volume Rendering Reconstruction in Helping the Diagnosis of Partial Thickness Subscapularis Tendon Tear**
Nathasiri L, Mamanee P, Sudhasaneyya V, Thongpak P, Laomahamek P, Issaragrisil P, Saksirinukul T
- 16 **A comparison of Patient Care Skills and Clinical Decision Making among Registered Nurses in Bangkok Hospital Rayong**
Phutthakanya N, Klongyut P, Buapin C, Techawattanasri P, Chanthawong J, Pornthaisong N, Witheesuwan P
- 23 **Compliance with Trauma Care Algorithms and Survival of Trauma Patients in Network of Private Hospitals in Thailand.**
Pundee C, Siriwanitchaphan W, Surakarn E

Case Report

- 29 **Chronic Silicosis as the Potential Consequence of Short-Term Exposure to Silica: A Case Report**
Tangsurased Kanruethai, Dumavibhat N, Chansaengpetch S, Virojskulcha T, Bunman S, Ingviya T, Jaroonpipatkul A, Thampibal T, Hathaivasiwong S, Buranasatitnon S, Phookjit T, Srihadom O, Oysrisakul N
- 33 **Chronic Idiopathic Granulomatous Mastitis in a Male Patient**
Likhitmaskul T, Aroonsiriwattana S
- 33 **Intradiploic Epidermoid Cyst Mimics a Bone Tumor: A Case Report**
Thammachantha S, Yuthagovit S, Hangsapruet S

Review Article

- 42 **Kratom Use and Health Literacy of Kratom for User: A Narrative Review**
Yothasupap A, Bunman S, Nomsiri A

Special Feature

- 49 **Developmental of 6 Cancer Risk Assessment Questionnaire; CRAQ-6 (Thai Version)**
Anamnant G, Sakjumba P, Wiriya T, Chaiwong W, Tonphu S, Sadangrit K,